


# Dermatopathology



Weill Cornell Medical College



Weill Cornell Physicians

## Excellence in Academic and Diagnostic Dermatopathology

We are pleased to announce that Weill Cornell Dermatopathology Services has established a Podiatric Pathology Division specifically to serve the needs of physicians of the lower extremity. We know that Podiatrists routinely require specialized and diverse testing in both anatomic and clinical pathology, therefore we have consolidated the requisition of these tests within the Weill Cornell Medical College/New York-Presbyterian Hospital. Our goal is to provide convenient access to our diagnostic services with consolidated reporting of results.

## Medical and Scientific Faculty

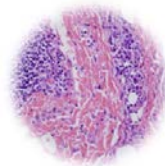


The Podiatric Pathology Division is under the direction of Dr. Cynthia M. Magro who is internationally renowned for her diagnostic expertise in complex inflammatory diseases, benign and malignant lymphocytic infiltrates, and diagnostically difficult melanocytic proliferations. Dr. Cynthia M. Magro received her training at Harvard Medical School. She is internationally known in dermatopathology, having co-authored over 280 papers, several book chapters and three textbooks *The Melanocytic Proliferation*, *The Cutaneous Lymphoid Proliferation*, and *Cutaneous Biopsy Interpretation*. She is also co-editor of the *Barnhill Textbook of Dermatopathology*. Her expertise has focused on the pathologic assessment of cutaneous autoimmune disease, viral disease, immunofluorescence, drug reactions, benign, atypical and neoplastic lymphocytic infiltrates of the skin and problematic melanocytic proliferations. She is a member of the American Society of Dermatopathology and United States and Canadian Academy of Pathologists.

## Referring physicians and their patients benefit from:

- ✓ Direct Access to expert consultation and case review with Dr. Magro
- ✓ Detailed therapeutic recommendations, if requested.
- ✓ Easy requisition of histopathology, microbiology, and small fiber neuropathy testing.
- ✓ Efficient, timely reporting.
- ✓ Routine diagnostic cases interpreted within 24 hours of specimen receipt.
- ✓ State of the art Histology and Medical Microbiology Laboratories.
- ✓ Utilization of a large array of immunohistochemical markers to assess neoplasia (i.e. Melan-A, sAC, etc.)
- ✓ Small fiber neuropathy, reflex sympathetic dystrophy and erythromyalgia testing.
- ✓ Direct and indirect immunofluorescence testing.
- ✓ Collaborative research opportunities.

## Services

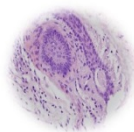


### ➤ **Routine Histopathologic Interpretation of Biopsied Tissue:**

- ✓ PSA stained light microscopic examination of nail plate or stratum corneum, which is more sensitive for detecting fungi than KOH or culture.
- ✓ Evaluation of pigmented lesions of the nail (subungual hemorrhage, subungual nevus, subungual melanoma).
- ✓ Evaluation of pigmented lesions of the foot and lower extremity (intracorneal hemorrhage, pigmented seborrheic keratosis acral lentiginous melanoma, superficial spreading melanoma).
- ✓ Evaluation of hyperkeratotic “scaly” lesions of the foot and lower extremity (seborrheic keratosis, porokeratosis, actinic keratosis, squamous cell carcinoma).
- ✓ Evaluation of nodular lesions of the foot and lower extremity (clear cell acanthoma, eccrine poroma, basal cell carcinoma, invasive squamous cell carcinoma, porocarcinoma).
- ✓ Routine cases require submission of a shave, punch, incisional, or excisional biopsy.

### ➤ **Specialized Inflammatory Skin Assessment for Cutaneous Manifestations of Autoinflammatory and Systemic Diseases:**

- ✓ We can assess any inflammatory cutaneous eruption to determine an exact etiology encompassing a broad spectrum of disorders including autoimmune vesiculobullous disease, vasculitis, collagen vascular disease and drug hypersensitivity reactions.
- ✓ Specialized inflammatory skin assessment requires submission of one punch biopsy cut into two halves (one submitted in formalin and one submitted in Michel’s solution for direct immunofluorescence).

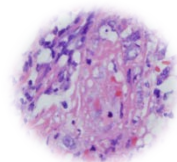


### ➤ **Small Fiber Neuropathy, Reflex Sympathetic Dystrophy and Erythromyalgia:**

- ✓ Routine light microscope with PGP 9.5 staining to assess autonomic nerve fiber density along with direct immunofluorescent testing may be of great value in the assessment of patients with possible small fiber neuropathy, erythromyalgia, and reflex sympathetic dystrophy and potentially provide information regarding possible etiology. Recent studies have shown that examining routine thin sections can provide accurate information regarding small fiber neuropathy by focusing on the autonomic nerve fiber network innervating the blood vessels, pilar erector muscle and eccrine coil. Conventional light microscope has the advantage of providing additional information such as the presence or absence of inflammation potentially pointing toward an autoimmune diathesis and or certain characteristic vascular changes seen in disorders such as glucose intolerance and porphyria. A single punch biopsy from the foot is required for this service. Concomitant direct immunofluorescent studies can provide additional clues in regards to varied etiologies of small fiber neuropathy including collagen vasculat disease, underlying diabetes, disorders of porphyrin metabolism, celiac disease, and paraproteinemia.
- ✓ Small fiber neuropathy, reflex sympathetic dystrophy and erythromyalgia assessment requires submission of one punch biopsy cut into two halves(one submitted in formalin and one submitted in Michel’s solution for direct immunofluorescence).

### ➤ **Microbiology Services**

- ✓ Specimens may be submitted to the New York-Presbyterian Hospital Microbiology Laboratory for bacterial and fungal cultures as well as antibody sensitivity testing.



For more information, consultation, or patient referral please contact us:

*Weill Cornell Medical College -Division of Dermatopathology*

*1300 York Avenue, Room F-310 ,New York, NY 10065*

*Tel. 212-746-6434 • Fax. 212-746-8570 • Website. [www.weillcornelldermpath.com](http://www.weillcornelldermpath.com)*